

# Autoimmunity and Immunodeficiency Coexisting in the Same Patient

Mugundhan Krishnan<sup>1</sup>, Kamatchi Sundaramoorthy<sup>2</sup>, Muralidharan Kamalakannan<sup>3</sup>, Sakthi Velayudham<sup>4</sup>, Sowmini Perumal<sup>5</sup>, Malcolm Jeyaraj<sup>6</sup>, Viveka Saravanan Raju<sup>7</sup>

Received on: 29 March 2022; Accepted on: 07 June 2022; Published on: 06 January 2023

## ABSTRACT

Myasthenia gravis is a well-known autoimmune disorder. Very few cases in literature showed association of myasthenia gravis, thymoma, and oral candidiasis. Here, we present a case of myasthenia gravis with thymoma, significant weight loss, extensive oral and esophageal candidiasis mimicking an immunodeficiency state which often creates a therapeutic dilemma in instituting immunosuppression.

**Keywords:** Acetylcholine receptor antibodies, Esophageal candidiasis, Good syndrome, Mucocutaneous candidiasis, Myasthenia gravis, Thymoma, Weight loss.

*Bengal Physician Journal* (2022): 10.5005/jp-journals-10070-7083

## BACKGROUND

Myasthenia gravis is a well-known and extensively studied autoimmune disorder, where antibodies are mediated against nicotinic receptors at neuromuscular junction. Antibodies against acetylcholine receptor (AChR) are detected in 80% of patients with myasthenia gravis.<sup>1</sup> About 10% have associated thymoma.<sup>1</sup> Approximately 40–50% of thymomas are associated with myasthenia gravis.<sup>1</sup> Here, we present a case of myasthenia gravis and thymoma presenting with significant weight loss, oral mucocutaneous, and esophageal candidiasis mimicking an immunodeficiency state.

## CASE DESCRIPTION

A 37-year-old female came with complaints of right eyelid drooping with diurnal variation of 2 years duration. She also complained of vomiting immediately after taking food, burning sensation in the mouth and heartburn in the previous 1 year and lost 15-kg body weight over this period, she also complained of head drop on and off over the past 3 months, difficulty in chewing and swallowing, difficulty in getting up from chair and squatting position, difficulty in combing and brushing, difficulty in lifting head from supine position, and dependent on her daughter for day-to-day activities due to fatigability over the past 3 months. She was investigated outside for immunodeficiency and malignancy which had no yield. On examination, she was pale with extensive oropharyngeal candidiasis and candidal stomatitis, she also had right eyelid ptosis (Fig. 1), bedside fatigability test was positive and quantitative myasthenia gravis (QMG) score was 15. Blood investigations mild iron deficiency anemia, renal, liver, and thyroid function tests were normal, and AChR was more than 8 nmol/L. Serum immunoglobulin G (IgG), immunoglobulin M (IgM), and immunoglobulin A (IgA) levels were normal; cluster of differentiation (CD4) and CD8 ratio was also normal. The repetitive nerve stimulation (RNS) testing showed decremental response of more than 10% in both orbicularis oculi. Computed tomography (CT) chest showed

<sup>1-7</sup>Department of Neurology, Stanley Medical College, Chennai, Tamil Nadu, India

**Corresponding Author:** Mugundhan Krishnan, Department of Neurology, Stanley Medical College, Chennai, Tamil Nadu, India, Phone: +91 9840444280, e-mail: mugundhan69@gmail.com

**How to cite this article:** Krishnan M, Sundaramoorthy K, Kamalakannan M, *et al.* Autoimmunity and Immunodeficiency Coexisting in the Same Patient. *Bengal Physician Journal* 2022;9(3): 73–74.

**Source of support:** Nil

**Conflict of interest:** Dr. Mugundhan Krishnan is associated as the Editorial Board Member of this journal and this manuscript was subjected to this journal's standard review procedures, with this peer review handled independently of the Editor-in-Chief and his/her research group.

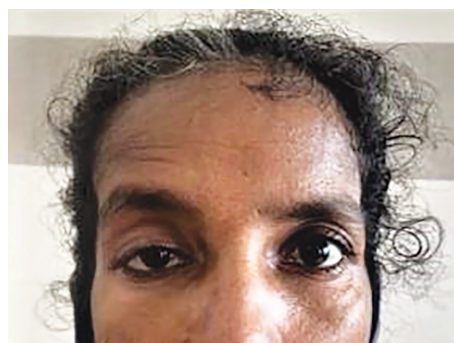


Fig. 1: Right eyelid ptosis

lobular mass in the anterior mediastinum without evidence of local infiltration suggestive of thymoma (Fig. 2). Computed tomography abdomen was normal. In view of recurrent vomiting, medical gastroenterology opinion was sought and upper gastrointestinal endoscopy was done which showed pangastritis with mid and lower esophageal candidiasis. Barium swallow showed shaggy

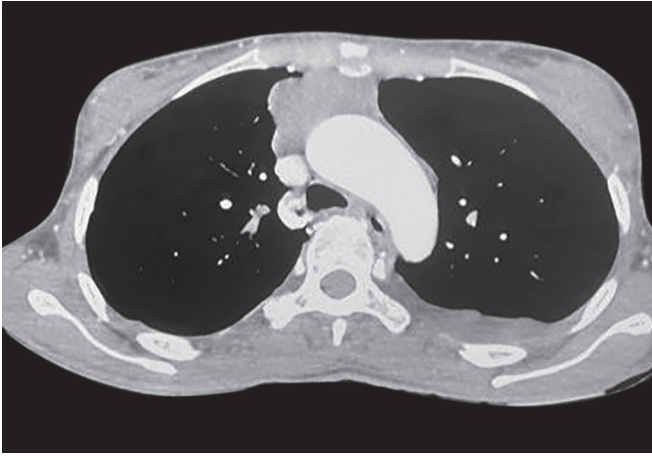


Fig. 2: Computed tomography scan showing lobular thymic enlargement

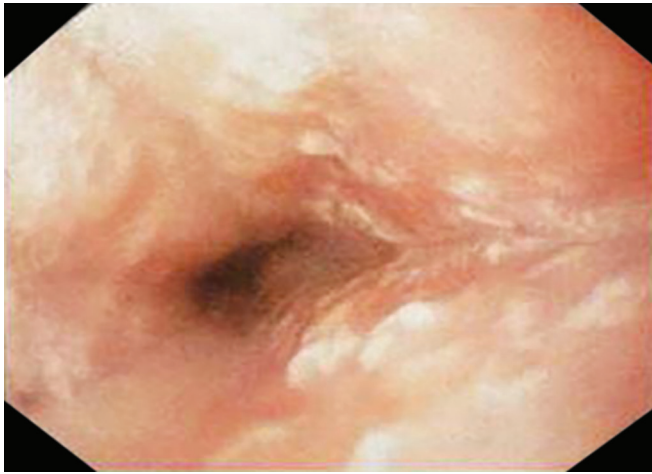


Fig. 3: Esophageal candidiasis

mid and lower esophagus suggestive of candidiasis. In view of oropharyngeal and esophageal candidiasis (Fig. 3), workup for HIV, HbSAg, HCV, and Good syndrome was done and was found to be negative.

## DISCUSSION

Very few cases have been published in literature showing association of myasthenia with thymoma and candidiasis. Boras et al. reported a case of myasthenia gravis with thymoma and oral candidiasis.<sup>1</sup> Such combination can occur in isolation or in association with good syndrome. Good syndrome is a rare-acquired immunodeficiency syndrome first described by Robert Good in 1954, which has got worst prognosis with mortality in the range 44–50%, when compared with other acquired immunodeficiency syndromes.<sup>2</sup> Moreover, 0.2–6% of thymomas are associated with Good syndrome.<sup>3</sup> This rare condition can present with variety of infections

such as *Pneumocystis carinii* pneumonia, cytomegalovirus (CMV) retinitis, disseminated aspergillosis, tuberculosis, and candidiasis, herpes zoster, Kaposi sarcoma, chronic diarrheal illness secondary to salmonella and shigella like any other immunodeficiency states.<sup>4</sup> Variety of autoimmune diseases are found to be associated with thymoma. Thymomas tend to release immature T cells into circulation. Normal thymic architecture is essential for normal development of T lymphocytes which is impaired in Thymoma.<sup>5</sup> However, in our case, workup for Good syndrome was negative. Porter and Scully reported that ulceration of tongue, buccal mucosa, and palate in patients with thymic tumor.<sup>6</sup> Rothberg et al. proposed screening for thymoma as a standard procedure in late onset severe and persistent oral candidiasis.<sup>7</sup> Often this association leads to decreased food intake and rarely spread of oral to esophageal candidiasis and further dissemination leading to higher mortality.<sup>8</sup> Often this immunodeficiency-like state creates a therapeutic dilemma in prescribing immunosuppressants. Our case was started on steroids, pyridostigmine and mycophenolate mofetil, proton pump inhibitors, and antifungals. Thymectomy was planned at a later date.

## CONCLUSION

The coexistence of myasthenia gravis, thymoma, and candidiasis in the same patient with features of autoimmunity and immunodeficiency proved to be diagnostic and therapeutic challenge. Recognition of this rare association is essential to decide long-term management of these patients.

## REFERENCES

1. Boras VV, Bralio V, Sostarko M. Candidiasis associated with thymoma and myasthenia gravis. *Oral Oncol Extra* 2005;41:56–59. DOI: 10.1016/j.ooe.2004.11.002.
2. Jansen A, van Deuren N, Miller J, et al. Prognosis of good syndrome: mortality and morbidity of thymoma associated immunodeficiency in perspective. *Clin Immunol* 2016;171:12–17. DOI: 10.1016/j.clim.2016.07.025.
3. Paronavitane S, Handagala S, De Silva R, et al. Thymoma complicated with myasthenia gravis and Good syndrome—a therapeutic conundrum: a case report. *J Med Case Rep* 2019;13(1):348. DOI: 10.1186/s13256-019-2289-z.
4. Grammatikos A, Donati M, Johnston SL, et al. Cell deficiency and predisposition to viral infections: the paradigm of immune deficiencies. *Front Immunol* 2021;12:731643. DOI: 10.3389/fimmu.2021.731643.
5. Weksler B, Lu B. Alteration of the immune system in the thymic malignancies. *J Thorac Oncol* 2014;9(Suppl. 2):S137–S142. DOI: 10.1097/JTO.000000000000299.
6. Porter SR, Scully C. Orofacial manifestations in primary immunodeficiencies: T lymphocyte defects. *J Oral Pathol Med* 1993;22:308–309. <https://doi.org/10.1111/j.1600-0714.1993.tb01078.x>.
7. Rothberg MS, Eisenbud L, GRiboff S. Chronic mucocutaneous candidiasis–thymoma syndrome. *Oral Surf Oral Med Oral Pathol* 1989;68:411–413. [https://doi.org/10.1016/0030-4220\(89\)90138-2](https://doi.org/10.1016/0030-4220(89)90138-2).
8. Lefebvre JL, Domenge C. A comparative study of efficacy and safety of fluconazole oral suspension and amphotericin B oral suspension in cancer patients with mucositis. *Oral Oncol* 2002;38:337–342. [https://doi.org/10.1016/s1368-8375\(01\)00063-x](https://doi.org/10.1016/s1368-8375(01)00063-x).